

Dental Amalgam and Mercury Levels in Autopsy Tissues

Food for Thought

Gianpaolo Guzzi, DDS,* Marco Grandi, MD,† Cristina Cattaneo, PhD,‡ Stefano Calza, MSc,§
Claudio Minoia, BSc,¶ Anna Ronchi, BSc,‡ Anna Gatti, BSc,‡ and Gianluca Severi, PhD||

Abstract: Eighteen cadavers from routine autopsy casework were subject to a study of tissue levels of total mercury in brain, thyroid, and kidney samples by atomic absorption. On these same cadavers, all dental amalgam fillings (the most important source of inorganic mercury exposure in the general population, according to the World Health Organization (WHO) were charted. Total mercury levels were significantly higher in subjects with a greater number of occlusal amalgam surfaces (>12) compared with those with fewer occlusal amalgams (0-3) in all types of tissue (all $P \leq 0.04$). Mercury levels were significantly higher in brain tissues compared with thyroid and kidney tissues in subjects with more than 12 occlusal amalgam fillings (all $P \leq 0.01$) but not in subjects with 3 or less occlusal amalgams (all $P \geq 0.07$).

Key Words: mercury, dental amalgams, forensic odontology

(*Am J Forensic Med Pathol* 2006;27: 42-45)

It rarely occurs that issues such as mercury, dental amalgam, or possible amalgam neurotoxicity may indeed reach the forensic scenario. However, scientific data have given us reason to at least consider the fact that dental amalgam may be a poison, in the strictest medicolegal sense, and that therefore its mode of distribution and accumulation within the body and consequential toxic effects could indeed have relevance from medicolegal perspective. However, much of the possible cause-effect concatenation still has to be proven, and the authors would like to briefly illustrate the results of the present pilot study to stimulate consideration of this issue, in other words as mere "food for thought."

Amalgam tooth fillings are considered to be the standard restorative material in the history of dentistry. From the

1970s until now, there has been considerable debate regarding the safety of dental amalgams. The controversy is based on the potential systemic adverse effects associated with the presence of mercury, including neurodegenerative diseases.¹

Current evidence suggests that mercury amalgam fillings are strongly associated with oral lichenoid lesions, a T-cell-mediated inflammatory disease. By contrast, there are no substantial data from prospectively clinical studies in human populations concerning systemic adverse health effects from dental amalgams.¹

In the present study, we investigated whether exposure to mercury vapor from amalgams in autopsy cases could be associated with mercury disposition in brain (frontal lobe cortex and pituitary gland), thyroid, and kidneys.

Dental amalgam is an intermetallic compound and contains approximately 50% elemental metallic mercury (Hg^0) by weight, 30-35% silver, 13-15% tin, 2-3% copper, and 1% zinc. Hg^0 vapor as monoatomic gas is released continuously from dental amalgam.^{1,2} Since the mixing compound is unstable due to mercury vapor, Hg^0 is emitted from dental amalgam over time. Mercury adsorbed per day from amalgam fillings ranges from 9 to 17 $\mu g/d$, with an uptake estimate of 12 $\mu g/d$.¹

Mercury vapor originating from amalgams and leaking out into the air of the oral cavity is correlated with dental amalgam surfaces: Hg^0 is absorbed readily (approximately 80% absorption rate) through the lung, crosses into the bloodstream, and is finally redistributed to all tissues, primarily to target organs. The biologic half-life of mercury vapor ranges from 20 to 90 days.^{1,3}

In essence, amalgam fillings have been shown to contribute to approximately two-thirds of the human body burden of mercury.²

The World Health Organization (WHO) considers amalgam fillings to be the primary source of inorganic and vapor mercury for the general population.² The amount of mercury from amalgam fillings clearly exceeds the combined amount of mercury from other sources: food (mainly derived from fish), water, and air.^{2,4}

In addition, the WHO states that the number of amalgam tooth surfaces and brain mercury levels at autopsy are related and that some mercury exposure is due to dental amalgam even though the levels in the brain are thought to be so low that adverse events may develop mainly in genetically susceptible individuals.⁵ However, it also points out that there is no safe level for mercury vapor in humans.⁴

Manuscript received October 5, 2004; accepted November 15, 2005.

From the *Italian Association for Metals and Biocompatibility Research (AIRMEB), Milan, Italy; †Institute of Legal Medicine, University of Milan, Milan, Italy; ‡Laboratory of Environmental and Toxicology Testing "S. Maugeri" (IRCCS), Pavia, Italy; §Department of Bioscience and Biotechnology, University of Brescia, Brescia, Italy; and the ||Cancer Epidemiology Centre, the Cancer Council, Victoria, Australia.

Reprints: Cristina Cattaneo, Istituto di Medicina Legale, Università degli Studi, Via Mangiagalli, 37, 20133 Milano, Italy. E-mail: cristina.cattaneo@unimi.it

Copyright © 2006 by Lippincott Williams & Wilkins

ISSN: 0195-7910/06/2701-0042

DOI: 10.1097/01.paf.0000201177.62921.e8

There is another source of mercury for humans: fish and shellfish. Owing to bioaccumulation of organic mercury, fish is considered a significant source of methyl mercury, which is the most important form of mercury in term of toxicity.¹ Substantially, predatory fishes are known to have the highest levels of methyl mercury, and it may affect specifically the developing human brain.⁶

Similarly, recent evidence has suggested an association between dental amalgams and organic mercury, as methyl mercury, in saliva in a case-controlled study.⁷

Mercury vapor toxicity is thought to be connected with a molecular binding of the mercury with endogenous ligand. More particularly, mercury has a high affinity for thiol-based proteins (-SH) like cysteine and glutathione (GSH).^{1,2} Such a mechanism entails an alteration of protein structure and function, resulting in potentially autoimmune reactions.¹

MATERIALS AND METHODS

Between March 1999 and September 2001, postmortem tissue samples were obtained from the routine autopsy casework of the Institute of Legal Medicine in Milan. The study was approved by the institutional review board from Institute of Legal Medicine.

Given the paucity of subjects with an elevated number of amalgam surfaces, cadavers were screened and selected according to the presence of dental amalgams in their teeth to be able to compare cases with a low number of amalgams with cases that had medium to high number of amalgam tooth restorations. A total of 18 cadavers (ie, cases) were selected (11 males and 7 females), with age ranging from 24 to 71. All cases were Italian, with the sole exception of 1 Peruvian. For each cadaver, number and extension of amalgam fillings were recorded on a dental chart.

The number of amalgams surfaces ranged from 0 to 28, with a median of 5. The age and sex distribution of the 3 cases with no amalgams was similar to that of the other cases.

Interviews with relatives prior to autopsy concluded that none of the subjects had occupational or accidental exposure to mercury, nor did they come from heavily polluted areas. From each of these subjects, 500 mg wet weight of tissue from frontal cortex (mixed white and gray matter), pituitary gland, thyroid gland, and kidney cortex were obtained and immediately frozen at -20°C. A number of specimens were excluded from the analysis because of technical reasons (ie, inadequate samples). The autopsy specimen tissue was analyzed by cold vapor atomic absorption (CVAA) to determine mercury content. Internal and external quality-control procedures were done.

For the statistical analysis, the number of occlusal amalgam surfaces was categorized in 3 groups, of 6 subjects each, using tertiles of the distribution (≤ 3 , 4-12, and >12 amalgam surfaces). The association between mercury levels, anatomic site, and number of amalgams was tested with a linear mixed effect model of the log concentrations, with anatomic site and number of occlusal amalgam surfaces as fixed effects and the subjects as random effects. This model allowed us to take into account the correlation of different measures in the same subject. The requirements of normally distributed residuals of the model were met.

RESULTS

The geometric means and 95% confidence intervals of the mercury levels by anatomic site and number of amalgams are shown in Figure 1. Mercury levels increased with the number of dental amalgams for all the anatomic sites. The interaction term between each anatomic site and the number of occlusal amalgam surfaces was statistically significant ($P =$

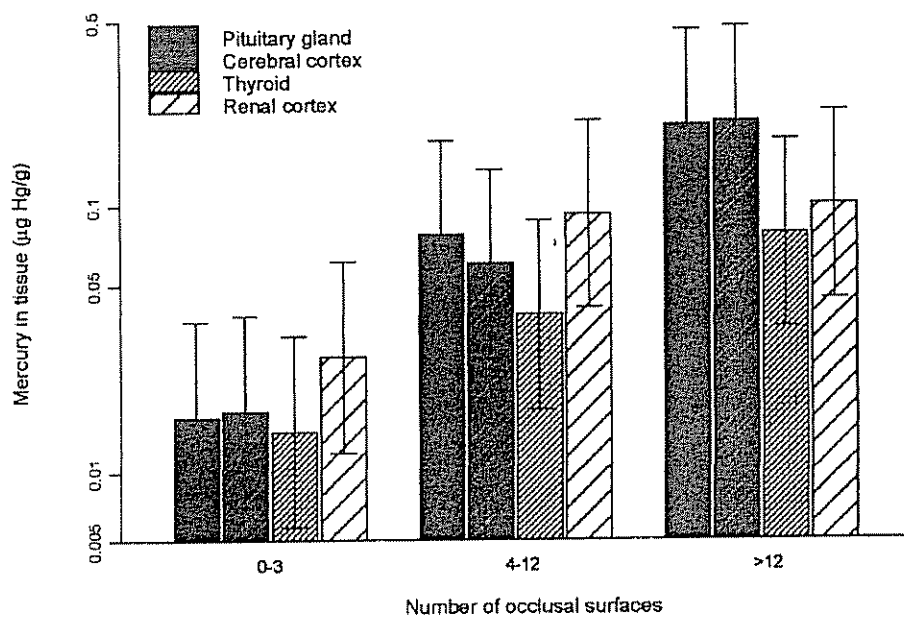


FIGURE 1. Total mercury levels by anatomic site and number of occlusal amalgam surfaces (geometric means and 95% confidence intervals).

0.03), suggesting that the association between mercury levels and the number of occlusal amalgams was dependent on the anatomic site. Mercury levels in the pituitary gland and the cerebral cortex in subjects with more than 12 occlusal amalgam surfaces were more than 10 times higher than levels in subjects with 3 or less occlusal amalgams (both $P = 0.0007$). Levels in the thyroid and in the renal cortex were respectively about 5 and 4 times higher in subjects with 12 occlusal amalgams or more compared with subjects with 3 occlusal amalgams or less ($P = 0.01$ and $P = 0.04$, respectively).

When using the number of occlusal amalgam surfaces as a continuous variable, the increase in mercury levels for each increment of 1 amalgam surface was highest and similar in the cerebral cortex and the pituitary gland (17% and 16%, respectively; P for trend <0.001 for both), medium in the thyroid (11%, $P = 0.01$), and lowest in the renal cortex (8%), for which the trend was not statistically significant ($P = 0.06$). Among subjects with more than 12 occlusal amalgams, the levels of mercury in the brain tissues were significantly higher than in the thyroid (both $P \leq 0.001$) and in the kidney (both $P = 0.01$), while among subjects with 3 amalgams or less, the levels in the brain tissues were similar to those in the thyroid and the renal cortex (all $P > 0.07$).

We then explored the number of occlusal amalgam surfaces and mercury levels by cause of death (suicide versus other). Among the suicide cases, there were 5 subjects (63%) with more than 12 occlusal amalgam surfaces compared with only 1 subject (10%) among the other cadavers ($P = 0.04$, Fisher exact test). The association between mercury levels in the different anatomic sites and the cause of death (suicide or other) was tested by using a model similar to that described above.

The levels of mercury in cases of suicide were higher than in the others in all the anatomic sites. The levels in the cases of suicide were, on average, about 3 times higher than in the others ($P = 0.04$), with no significant variation in this difference by anatomic site (P for interaction = 0.3). The inclusion of age and sex in the models did not significantly modify the estimates. We were unable to accurately determine the exact data on the frequency of fish consumption for each subject.

DISCUSSION

In this investigation, we found that the number of occlusal amalgam surfaces was associated with the total mercury levels in a number of human tissues with highest levels observed in the frontal cortex. Consistent with our findings, other studies have shown a correlation between the total amalgam surfaces and total mercury tissue concentration in human autopsy tissue samples.^{3,8}

Previous autopsy data from cases of exposure to dental amalgam fillings revealed that there is a positive correlation between number of total amalgam surfaces and mercury disposition in human organs and tissues.^{2,4,8,9}

Moreover, maternal-to-fetus transfer of mercury from amalgams has also been reported in human autopsy studies, and the total mercury has been found to be elevated in the cerebral cortex, liver, and renal cortex of fetuses/older in-

fants, and its level correlates to the number of maternal amalgam surfaces.⁹ Similarly, such findings have been supported by animal experiments.²

The occurrence of inorganic mercury in fetal tissues is thought to correlate with inorganic mercury in cord blood. Mercury vapor from amalgams is very likely to pass easily through the placenta unchanged.^{10,11}

Despite its importance, this work has 2 limitations. No information was recorded about fish consumption during pregnancy, and the lack of specific data did not allow us to determine whether some of the participants were occupationally or environmentally exposed to mercury. In spite of these limitations, the study makes a valuable contribution to our understanding on mercury disposition in fetuses and infants. Thus, the association between dental amalgams and mercury disposition in fetus and/or child is still to be confirmed with further investigation.

On the other hand, evidence that mercury vapor can sidestep the placenta comes from a cross-sectional study based on mercury determination in mother-newborn pairs. Owing to amalgams, substantially elevated levels of mercury were found both in maternal and fetal hair compared with controls.¹²

Our survey did comply with the results of previous studies, suggesting that there is a significant disposition of mercury originating from dental amalgams. Also our findings are partially consistent with the results of experiments in animal models.²

Unexpectedly, our investigation differs from most previous studies as higher levels of total mercury in pituitary gland were not observed compared with brain cortex. In fact, there was no significant difference in total mercury content between pituitary gland and frontal cortex.

Given the lack of histopathology studies, the small sample size, and no mercury speciation in autopsied tissues, we deliberately chose to be cautious and not to overinterpret this finding.

Our study is very small and was specifically designed to study the association between the number of amalgams and mercury in tissues. The finding concerning suicides, which we clearly describe in the results, is interesting but derives from an a posteriori analysis, and, given the small sample size, we cannot rule out the role of chance.

The speculative link between chronic exposure to mercury vapor and suicidal behavior in dentists has been observed in previous studies.¹³ In support of this, the chronic exposure to mercury vapor is also suspected to contribute to increasing the risk associated with suicidal behavior in mercury miners.¹⁴ Certainly, the systemic level of exposure to mercury vapor is higher in dentists and, particularly, in mercury and gold miners with respect to individuals who are exposed solely to dental amalgams.

In summary, our research shows, for the first time, that frontal lobe cortex has the highest content levels of mercury associated with occlusal amalgam surfaces and total mercury levels approaching or exceeding 300 ppb (ng/g), wet weight, in some cases. This, in turn, strongly points to the hypothesis—

which, in the future, should be looked into in larger and ad hoc studies—that mercury vapor, known to be a neurotoxicant,¹ may indeed lead to some types of neurobehavioral disorders.

ACKNOWLEDGMENTS

We are indebted to Giuseppe Remuzzi, Norberto Perico, and David Eggleston for their cooperation, valuable comments, and discussion.

REFERENCES

1. Clarkson TW. The three modern faces of mercury. *Environ Health Perspect*. 2002;110(suppl 1):11–23.
2. Lorscheider LF, Vimy MJ, Summers AO. Mercury exposure from “silver” tooth fillings: emerging evidence questions a traditional dental paradigm. *FASEB J*. 1995;9:504–508.
3. Mark Richardson G, Allan M. A Monte Carlo assessment of mercury exposure and risks from dental amalgam. *Human Ecol Risk Assess*. 1996;2,4:709–761.
4. World Health Organization. *Inorganic mercury: Environmental Health Criteria 118. International Programme on Chemical Safety*. Geneva: World Health Organization; 1991.
5. World Health Organization. The hazard of mercury. *IPCS News* March 1992;1:4–5. Available at: <http://www.who.int/ipcs/publications/newsletters/en/01.pdf>.
6. Clarkson TW, Magos L, Myers GJ. Current concepts: the toxicology of mercury: current exposures and clinical manifestations. *N Engl J Med*. 2003;349:1731–1737.
7. Leisteuvo J, Leisteuvo T, Helcinius H, et al. Dental amalgam fillings and the amount of organic mercury in human saliva. *Caries Res* 2001;35: 163–166.
8. Eggleston DW, Nylander M. Correlation of dental amalgam with mercury in brain tissue. *J Prosthet Dent*. 1987;58:704–707.
9. Drasch G, Schupp I, Hoff H, et al. Mercury burden of human fetal and infant tissues. *Eur J Pediatr*. 1994;153:607–610.
10. Lutz E, Lind B, Herin P, et al. Concentrations of mercury, cadmium and lead in brain and kidney of second trimester fetuses and infants. *J Trace Elem Med Biol*. 1996;10:61–67.
11. Vahter M, Akesson A, Lind B, et al. Longitudinal study of methylmercury and inorganic mercury in blood and urine of pregnant and lactating women, as well as in umbilical cord blood. *Environ Res* 2000;84:186–194.
12. Lindow SW, Knight R, Batty J, et al. Maternal and neonatal hair mercury concentrations: the effect of dental amalgam. *BJOG*. 2003;110: 287–291.
13. Arnetz BB, Horte LG, Hedberg A, et al. Suicide among Swedish dentists: a ten-year follow-up study. *Scand J Soc Med*. 1987;15:243–246.
14. Grum DK, Arnerič N, Kobal AB, et al. Can occupational exposure to elementary mercury increase the risk of suicide? *RMZ Materials Geoenviron*. 2004;51:452–457.